

# Histological features of knee joint meniscus injuries of the professional athletes practicing various types of sports activities.

VADIM KASIMOV<sup>1</sup>, ANDREY RUSSKIH<sup>2</sup>, ANNA SHABOKHA<sup>2</sup>, ALEKSANDER OSIPOV<sup>2,3,4</sup>, TATYANA ZHAVNER<sup>3</sup>, ANNA VAPAEVA<sup>3</sup>

<sup>1</sup>Krasnoyarsk district clinical hospital №7, Krasnoyarsk, RUSSIA

<sup>2</sup>Krasnoyarsk State Medical University named after professor V.F. Voyno-Yasenetsky, Krasnoyarsk, RUSSIA

<sup>3</sup>Siberian Federal University, Krasnoyarsk, RUSSIA

<sup>4</sup>Siberian Law Institute of the Ministry of Internal Affairs of the Russian Federation, Krasnoyarsk, RUSSIA

E-mail: [ale44132272@yandex.ru](mailto:ale44132272@yandex.ru)

**Abstract:** A significant amount of the training loads increases the risk of injury during the athletic training for the athletes. The physicians note a significant increase of the knee joints injuries of the athletes associated with the injuries of the meniscus. The article research of the authors is aimed at determining possible features of the histological structure of the injured meniscus of the knee joints of the athletes practicing different kinds of sports (game-oriented sports and martial arts). Therefore in this study, the biopsy materials were examined during the arthroscopic intervention. It was revealed that meniscus of the knee joints of the athletes practicing martial arts are more susceptible to structural histological changes at the level of the posterior horn. The prevalence of isogenic groups of chondrocytes with a minimal number of individual and hypertrophied chondrocytes is revealed. Histological features of the structure of damaged meniscus of the athletes practicing game-oriented sports are characterized by an increase in the number of the individual chondrocytes with a minimal amount of isogenic groups of the chondrocytes at the level of the anterior horn of the meniscus. The revealed histological features of the damaged meniscus of the professional athletes can be successfully used in the process of rehabilitation selecting the chondroprotective therapy and special exercises that help to strengthen the damaged parts of the ligament apparatus of the knee joints of the athletes.

**Key words:** injuries; game-based sports; martial arts; knee joint injury; meniscus injury; biopsy materials; chondrocytes.

## Introduction

Training and competitive loads in different kinds of sports activities do not only contribute to improving the level of preparedness of the athletes but also are a significant factor in the increased risk of injury. The problems of traumatism during the different kinds of sports are one of the leading places in the scientific research of the sports medicine and rehabilitation of the athletes. Traumatism is a key reason for the decline of the sport results and the termination of an active sports career. The majority of sports injuries are caused by the musculoskeletal system of the athletes: the vertebral column (Botov, Shnyakin, Osipov, et al., 2018), joints and ligaments (Bolotin, & Bakayev, 2016). At the same time, there is a fairly close relationship between the magnitude and specificity of the training loads and the nature of sports injuries (Moh'd Abdel Kader, & Nikanorov, 2012).

Meanwhile, the experts note a significant increase of knee joints traumatism of the athletes associated with meniscus injuries (Barber, & McNally, 2013). Both adults and young athletes have the similar injuries and are usually the result of the action of compressive forces on the knee flexuous and turned towards the side knee (Zedde, Mela, Del Prete, et al., 2014). Most often, such injuries happen to the athletes representing game-based sport: football, basketball, volleyball, rugby but there has been a fair number of meniscus injuries which the athletes from other sports have (Poulsen, & Johnson, 2011). In particular, the elite judoists have high risks of knee injury (Osipov, Kudryavtsev, Iermakov, et al., 2017; Pérez-Turpín, Penichet-Tomás, Suárez-Llorca, et al., 2013). The experts note that the likelihood of injury is the same for both the right and left knees of the professional athletes and increases with the age (Lariosa, Gozdowski, Pietkiewicz, et al., 2017) and body weight growth (Yeh, Starkey, Lombardo, et al., 2012). Most meniscus injuries occur directly in competitions and the structure of injuries depends on the gender of the athletes (Terzidis, Christodoulou, Ploumis, et al., 2006) and the sport (Mitchell, Graham, Best, et al., 2016). Meniscus injuries cause severe pain and accelerate the progress of osteoarthritis of the knee (Hasan, Fisher, & Ingham, 2014; Makris, Hadidi, & Athanasiou, 2011). The studies show that the effectiveness of the athletic activities of the athletes returning to the sport after a meniscus injury is reduced (Costa-Astur, Xerez, Rozas, et al., 2016).

The scientists believe that in order to reduce the level of injuries meniscus knee joints significantly, it is necessary to raise awareness about the nature of injuries (Mitchell, Graham, Best, et al., 2016). Having the necessary knowledge will help to develop scientifically base strategies for effective prevention of this type of injury. Experts also argue that many of the tests are available to assess the severity of meniscus damage which is not completely reliable. It is necessary to focus on developing the new techniques for accurate assessment and predicting possible damage to the meniscus (Chivers, & Howitt, 2009). There are cases where surgery is not fully effective for sports injuries of the meniscus in the form of the arthroscopy. Such cases are possible because the biopsy material is not always sampled for a detailed histological examination of the meniscus injuries. A histological study based on the biopsy material is

necessary to select the appropriate and effective treatment, prevent injuries and rehabilitate the athletes successfully. In some cases, the risk of recurrence of a meniscus injury is high enough which in its turn leads to the chronic traumatism and the end of a sports career. The opinion of the authors of the article is a detailed study of the histological structure of the arthroscopic biopsies of the meniscus knee joints of the traumatized athletes will let to identify possible risks of the progressive degenerative changes and select appropriate treatment tactics.

In connection with the above, the authors of the article determined the purpose of their studies to estimate the possible features of the histological structure of damaged meniscus of the knee joints of the professional athletes practicing various types of sports activities.

## Material & methods

It may seem that the studies of the histological features of meniscus injuries of the knee joints of the professional athletes were conducted on the basis of the laboratory of Krasnoyarsk State Medical University named after Professor V.F. Voyno-Yasenetsky (Krasnoyarsk, Russia). For the study, the biopsy materials of the body, anterior and posterior horns of the meniscus were obtained which were obtained during the arthroscopic interventions. Moreover, the materials were taken from 32 professional athletes (men) in the period from 2012 to 2017. All athletes were examined for the knee joint injuries. Frankly speaking, the average age of the athletes is  $26.5 \pm 1,8$  years. All examined athletes gave their consent to participate in the research. All ethical norms and principles have been met in full. The studies were approved by the local ethics committee of the Krasnoyarsk State Medical University named after Professor V.F. Voyno-Yasenetsky (Minutes No. 39 of 28.03.2012).

In recent years, after a standard fixation of the biological material taken from the athletes in 10% formalin solution sections of the meniscus biopsy were prepared at the level of their anterior and posterior horns and also of the body. It was revealed that hematoxylin-eosin-stained histological specimens were subjected to survey microscopy, description and morphometry of the sections of the knee joint meniscus specimens. The chondrocyte diameters were counted at one or another level of the meniscus cut, the number of the single lying cells and the number of isogenic groups per unit area of unchanged cartilaginous tissue of the studied sections. When assessing the results of the histological examination, the authors took into account the belonging of the athletes to sports activities. 18 athletes from 32 patients were engaged in game-based sport (football and volleyball) and 14 athletes were engaged in various martial arts (judo, freestyle and Greco-Roman wrestling).

As a matter of fact, statistical processing of the results of the studies was carried out using the statistical analysis program SPSS Statistics 17.0. The normality of the distribution of the results was determined on the basis of the Shapiro-Wilk criterion. We must admit when comparing two independent data samples a non-parametric Mann-Whitney test (U-test) was used. This criterion is the most used to determine the reliability of differences in the results of small sample sizes of the studied patients.

## Results

In addition, the studies show that the cartilage structure of both internal and external meniscus of both knee joints of the examined athletes consists of a zone of the perichondrium where the individual chondroblasts of spindle-shaped form and zones of young and mature cartilages that do not have a clear boundary are visualized. Against the background of the prevailing intercellular substance the isogenic groups of chondrocytes are found enclosed in lacunae. These clusters, as a rule, include from 2 to 4 cells. The described structure is characteristic for all levels of the histological sections of both meniscuses regardless of the side of the examination of the knee joints of the athletes. Actually, the main results of a histological study are devoted to identifying the features of meniscus injuries of the knee joints of the professional athletes are presented in Table 1.

Table 1. Histological characteristics of the knee joint meniscuses of the professional athletes (n = 32) who are engaged in various sports activities.

Parameter	Level of research	Game-based sports (n = 18)	Martial Arts (n = 14)
The average diameter of the chondrocytes ( $\mu\text{m}$ )	Anterior horn of the meniscus	11,33 $\pm$ 0,16	11,55 $\pm$ 0,21*
	The body of the meniscus	12,10 $\pm$ 0,07	12,48 $\pm$ 0,12*
	Rear horn of the meniscus	12,15 $\pm$ 0,17	13,08 $\pm$ 0,14*
Number of individual cells (conventional units)	Anterior horn of the meniscus	15,41 $\pm$ 0,06	15,72 $\pm$ 0,18*
	The body of the meniscus	12,23 $\pm$ 0,14	13,22 $\pm$ 0,16*
	Rear horn of the meniscus	13,43 $\pm$ 0,17*	11.14 $\pm$ 0,23
The number of isogenic groups of chondrocytes (conventional units)	Anterior horn of the meniscus	0,52 $\pm$ 0,01	1,31 $\pm$ 0,06*
	The body of the meniscus	1,02 $\pm$ 0,04	1,83 $\pm$ 0,08*
	Rear horn of the meniscus	1,22 $\pm$ 0,13	2,32 $\pm$ 0,15*

Accuracy - \* - P <0,05.

First of all, the fact of statistically significant ( $P < 0.05$ ) differences of the investigated parameters at the level of the horn of the meniscus of the athletes who are professionally engaged in martial arts (for example judo). The average diameter of the chondrocytes of the meniscus of the knee joint is  $13.08 \pm 0.14 \mu\text{m}$  which is significantly ( $P < 0.05$ ) higher than the value of this index at the level of the body and the anterior horn of the meniscus. Also, the athletes practicing martial arts found a characteristic feature of the minimum number of individual cells -  $11.14 \pm 0.23$  at the level of the horn of the meniscus with the value of this parameter -  $13.22 \pm 0.16$  in the body area of the meniscus and  $15.72 \pm 0.18$  in the projection of the anterior horn of the meniscus. The martial artists have the maximum value of the number of isogenic groups of chondrocytes in the area of the body as well as in the anterior and posterior horn of the meniscus. Moreover, the studies show that the structure of the meniscus tissue is not uniform with a fairly chaotic arrangement of isogenic groups of chondrocytes and a tattered perichondrium. In the cartilage zones of the meniscus the number of chondrocytes is visually increased isolated hypertrophied chondrocytes with the phenomena of karyopycnosis and karyorexis are isolated and the number of isogenic groups also increases (Figure 1).

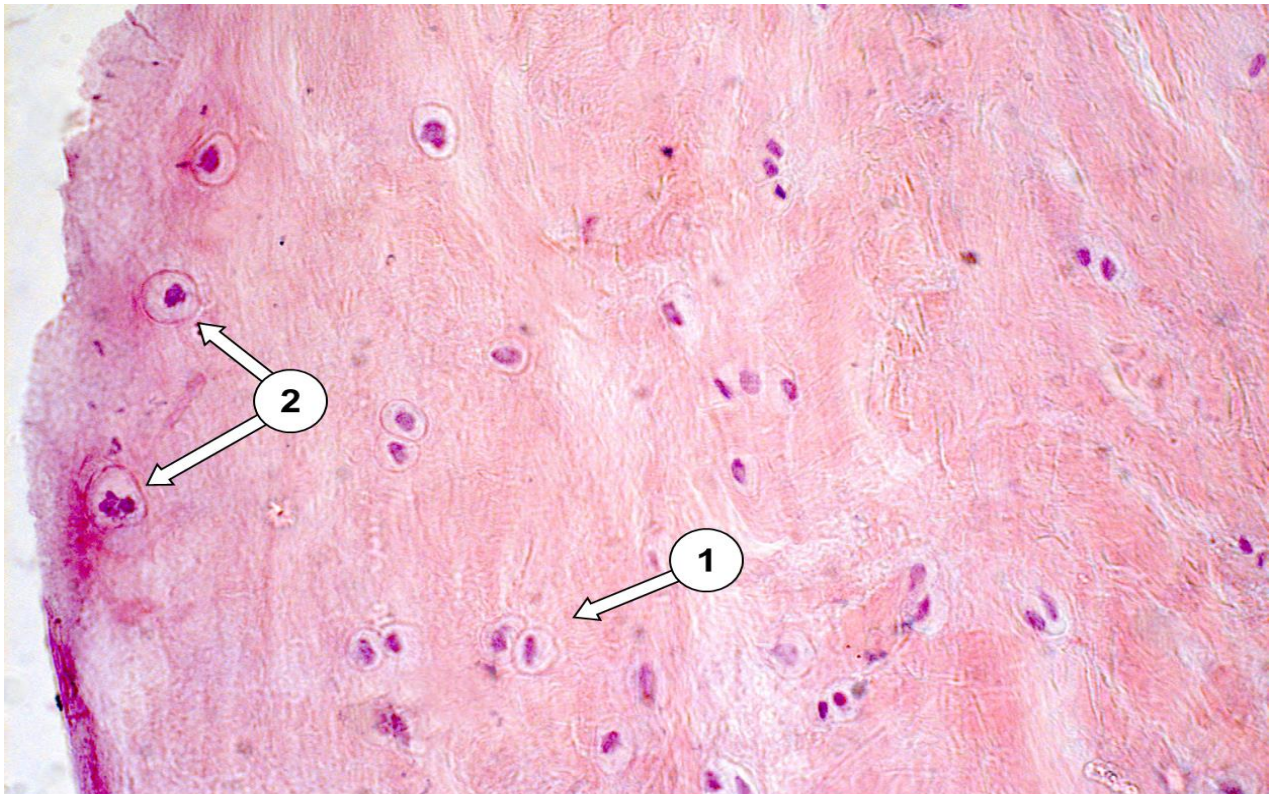


Fig. 1. Hyaline cartilaginous tissue of the posterior horn of the medial meniscus of the right knee joint of the athlete practicing martial arts (judo).

1 - Isogenic group of chondrocytes;

2 - A single chondrocyte with the phenomena of karyopycnosis and karyorexis.

At the same time, it is estimated that comparative analysis of the menometric morphometric parameters at the level of the horn of the athletes practicing martial arts and the athletes engaged in game-based sports (football and volleyball) demonstrates the presence of statistically significant differences. It was revealed that at the level of the horn of the meniscus and the average diameter of chondrocytes of the athletes practicing single combat is significantly ( $P < 0.05$ ) more than the athletes practicing sports games. An important point is that the number of isogenic groups of chondrocytes is also significant ( $P < 0.05$ ) more for the martial artists -  $2.32 \pm 0.15$  than for the athletes from game-based sports -  $1.22 \pm 0.13$ . It should be noted that the significant prevalence of the number of individual cells of the athletes from the game sports is  $13.43 \pm 0.17$  compared to the single fighters -  $11.14 \pm 0.23$ . The scientists believe that the athletes who are engaged in game-based sports are dominated by a homogeneous structure of the meniscus of the knee joints with a flat perichondrium, the absence of hypertrophied chondrocytes and their fairly stable average diameter at different levels of the cut (Figure 2).

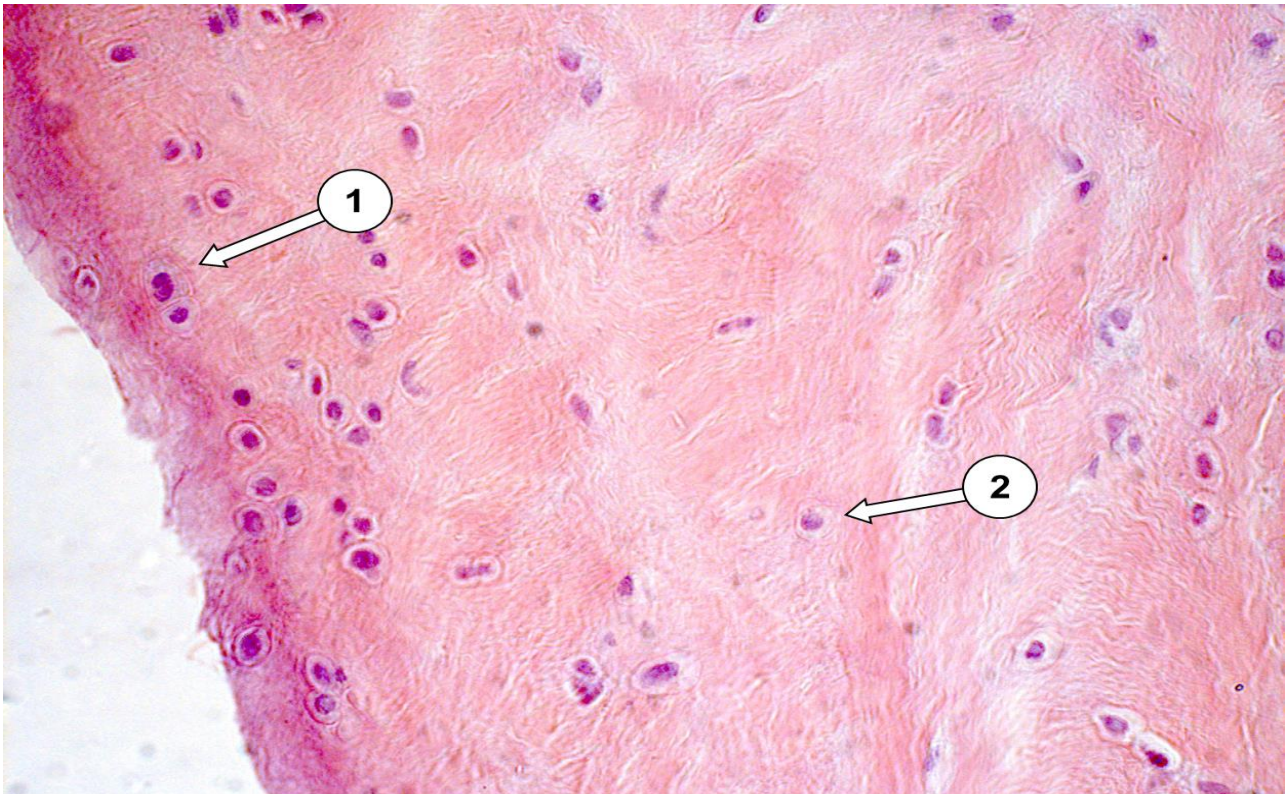


Fig. 2. Hyaline cartilaginous tissue of the posterior horn of the medial meniscus of the right knee joint of the athlete practicing game-based sports (volleyball).

1 - Isogenic group of chondrocytes;  
2 - A single chondrocyte.

It is important to note that the differences in the values of the number of chondrocytes and the number of isogenic groups of the chondrocytes among the athletes practicing game-based sports activities were found also statistically significant ( $P < 0.05$ ). The number of chondrocytes at the level of the anterior horn of the meniscus is  $15.41 \pm 0.06$  which is significantly ( $P < 0.05$ ) higher than the values of this parameter at the level of the meniscus body -  $12.23 \pm 0.14$  and the horn -  $13, 43 \pm 0,17$  among the athletes. Nevertheless, on the contrary the number of isogenic groups of chondrocytes at the level of the anterior horn has a minimum in comparison with other levels where a value is  $0.52 \pm 0.01$ . In the area of the meniscus body this parameter is equal to  $1.02 \pm 0.04$  and at the level of the posterior horn is  $1.22 \pm 0.13$ .

## Discussion

Actually, the scientists argue that injuries are an integral part of the professional sports activities and should be considered as an inevitable fee for achieving sports results and competition in sports. However, an incorrect diagnosis or poor-quality treatment can lead to incomplete recovery, the appearance of chronic syndromes and in the long term cause degenerative changes in the joints (Maffulli, Longo, Gougoulis, et al., 2011). For example, the knee joint injuries with insufficient or incorrect treatment can lead to the development of osteoarthritis (Kapustina, Bolshakova, Sharaikina, et al., 2013; Moh'd Abdel Kader, & Nikanorov, 2011). As a result, the doctors say that the accurate data on the restoration of damaged meniscus functions both after arthroscopy and without surgical intervention (Moh'd Abdel Kader, & Mohammadreza are needed to determine the effective methodological approaches and develop a program for qualitative rehabilitation of athletes with injuries to the medial meniscus, 2012).

All in all, the specialists in the field of orthopedics and traumatology note that there has been a significant shift in the perception of the role of the meniscus in the activity of the knee joint over the last two decades in medicine (Beaufils, Becker, Kopf, et al., 2017). Moreover, it should be noted that the basic scientific research attempts to examine the impact of injury and subsequent restoration of the meniscus on the function of the knee joint as a whole (Hutchinson, Moran, Potter, et al., 2014). It has been revealed that the meniscus is a complex tissue and requires rather extensive clinical studies devoted to the search for effective methods of healing or meniscus replacement. Furthermore, the problem is that, in view of the histological features, the cartilaginous tissue has low recovery ability. Consequently, the ability of the meniscus to recover is severely limited (Korpershoek, de Windt, Hagmeijer, et al., 2017). As a result of the above indicates the damage to the meniscus can lead to tissue degeneration and cause chronic diseases (Wang, Yuan, Ma, et al., 2017). Unfortunately, the modern methods of treating damaged meniscus have a large number of negative long-term results which pushes doctors to replace meniscus (Liang, Idrees, Andrews, et al., 2017). However, even a meniscus replacement is characterized by a high level of complications, pain symptoms and recurrence of trauma (Hauser, Phillips, & Maddela, 2010). It goes without saying that the presence of the comprehensive knowledge of the

meniscus is necessary for physicians to perform effective surgical intervention and subsequent rehabilitation of the patients. To maintain the level of normal activity of the knee joints of patients the physicians need to preserve the unique biomechanical and histological properties of the meniscus (Brindle, Nyland, & Johnson, 2001).

As a matter of fact, the study is conducted by the authors of the article which shows the presence of peculiarities of the histological structure of meniscus lesions of the knee joints of the athletes practicing different kinds of sports. Additional evidence has been found that the characteristics of the professional activity of the athletes can reflect on the microstructure of the meniscus knee joints at their various levels. It should be noted that the meniscus of the knee joints of the athletes practicing different types of the martial arts are subject to structural changes in the histological pattern at the level of the posterior horn where a significant predominance of the number of isogenic groups of chondrocytes with a minimal number of chondrocytes enlarged in diameter (hypertrophied) is revealed. Also, the histological structure of the damaged meniscus of the athletes representing game-based sports is characterized by an increase in the number of individual chondrocytes with a minimal amount of isogenic groups of chondrocytes at the level of the anterior horn of the meniscus compared to the other parts.

## Conclusions

It is generally agreed today that some histological features of the meniscus injury of the professional athletes representing game-based sports and single combat were found by the article authors and can be used for the individual selection of chondroprotective therapy in the rehabilitation period. Also, the research data may influence the choice of certain exercises in the rehabilitation course of the athletes which help to strengthen the specific areas of the ligament apparatus of the knee joints of the athletes who injured meniscus during sports activities. Further clinical studies are needed to find the effective methods of the treatment and rehabilitation of the damaged meniscus.

**Conflicts of interest** - If the authors have any conflicts of interest to declare.

## References.

- Barber, B., & McNally, E. (2013). Meniscal injuries and imaging the postoperative meniscus. *Radiologic clinics of North America*, 51(3). 371-391. DOI:10.1016/j.rcl.2012.10.008
- Beaufils, P., Becker, R., Kopf, S., Matthieu, O., & Pujol, N. (2017). The knee meniscus: management of traumatic tears and degenerative lesions. *Efort Open Reviews*, 2. DOI:10.1302/2058-5241.2.160056
- Bolotin, A., & Bakayev, V. (2016). Efficacy of using isometric exercises to prevent basketball injuries. *Journal of Physical Education and Sport*, 4. 1177-1185. DOI:10.7752/jpes.2016.04188
- Botov, A., Shnyakin, P., Osipov, A., & Zhavner, T. (2018). Search for effective treatment techniques for professional athletes with lower back pain. *Journal of Physical Education and Sport*, 1. 17-22. DOI:10.7752/jpes.2018.01002
- Brindle, T., Nyland, J., & Johnson, D. (2001). The meniscus: Review of basic principles with application to surgery and rehabilitation. *Journal of Athletic Training*, 36(2). 160-169.
- Chivers, M., & Howitt, S. (2009). Anatomy and physical examination of the knee menisci: a narrative review of the orthopedic literature. *The Journal of the Canadian Chiropractic Association*, 53(4). 319-333.
- Costa-Astur, D., Xerez, M., Rozas, J., Vargas Debieux, P., Franciozi, C., & Cohen M. (2016). Anterior cruciate ligament and meniscal injuries in sports: incidence, time of practice until injury, and limitations caused after trauma. *Revista Brasileira de Ortopedia (English Edition)*, 51(6). 652-656. <https://doi.org/10.1016/j.rboe.2016.04.008>
- Hasan, J., Fisher, J., & Ingham, E. (2014). Current strategies in meniscal regeneration. *Journal of Biomedical Materials Research. Part B, Applied Biomaterials*, 102(3). 619-634. DOI:10.1002/jbm.b.33030
- Hauser, R., Phillips, H., & Maddela, H. (2010). The case for utilizing prolotherapy as first-line treatment for meniscal pathology: A retrospective study shows prolotherapy is effective in the treatment of MRI-documented meniscal tears and degeneration. *Journal of Prolotherapy*, 2(3). 416-437.
- Hutchinson, I., Moran, C., Potter, H., Warren, R., & Rodeo, S. (2014). Restoration of the meniscus: form and function. *The American Journal of Sports Medicine*, 42(4). 987-998. DOI:10.1177/0363546513498503
- Kapustina, E., Bolshakova, T., Sharaikina, E., Chupahina, V., & Panchenko, T. (2013). Osteoporotic fractures in patients with osteoarthritis. *Siberian Medical Review*, 2(80). 59-61. [In Russian]
- Korpershoek, J., de Windt, T., Hagmeijer, M., Vonk, L., & Saris, D. (2017). Cell-based meniscus repair and regeneration: At the brink of clinical translation?: A systematic review of preclinical studies. *Orthopaedic Journal of Sports Medicine*. <https://doi.org/10.1177/2325967117690131>
- Lariosa, C., Gozdowski, D., Pietkiewicz, S., & Maciejewski, R. (2017). Survey of judo injuries in physical education classes: a retrospective analysis. *Journal of Physical Education and Sport*, 3. 2034-2042. DOI:10.7752/jpes.2017.03205
- Liang, Y., Idrees, E., Andrews, S., et al. (2017). Plasticity of human meniscus fibrochondrocytes: A study on effects of mitotic divisions and oxygen tension. *Scientific Reports*, 7. 12148. DOI:10.1038/s41598-017-12096-x
- Maffulli, N., Longo, U., Gougoulias, N., Caine, D., & Denaro, V. (2011). Sport injuries: a review of outcomes. *British Medical Bulletin*, 97(1). 47-80. <https://doi.org/10.1093/bmb/ldq026>
- Makris, A., Hadidi, P., & Athanasiou, K. (2011). The knee meniscus: Structure–function, pathophysiology, current repair techniques, and prospects for regeneration. *Biomaterials*, 32(30). 7411-7431. <https://doi.org/10.1016/j.biomaterials.2011.06.037>

- Mitchell, J., Graham, W., Best, T., Collins, C., Currie, D., Dawn Comstock, R., & Flanigan, D. (2016). Epidemiology of meniscal injuries in U.S. high school athletes from 2007/08 – 2012/13. *Knee Surgery Sports Traumatology Arthroscopy*, 24(3). 715-722. DOI:10.1007/s00167-015-3814-2
- Moh'd Abdel Kader, M., & Mohammadreza, P. (2012). Features of the construction program of physical rehabilitation of athletes playing sports with damage to the medial meniscus of knee. *Physical Education of Students*, 5. 69-73.
- Moh'd Abdel Kader, M., & Nikanorov, A. (2012). Some aspects of damage of medial meniscus of knee-joint for the sportsmen of playing types of sport. *Physical Education of Students*, 2. 74-77.
- Moh'd Abdel Kader, M., & Nikanorov, A. (2011). The modern view of the physical rehabilitation of damaged medial meniscus in the knee joint in athletes. *Pedagogics, psychology, medical-biological problems of physical training and sports*, 11. 82-85.
- Osipov, A., Kudryavtsev, M., Iermakov, S., & Jagiello, W. (2017). Topics of doctoral and postdoctoral dissertations devoted to judo in period 2000-2016 – the overall analysis of works of Russian experts. *Archives of Budo*, 13. 1-10.
- Pérez-Turpín, J., Penichet-Tomás, A., Suárez-Llorca, C., Jiménez-Olmedo, J., Jove-Tossi, M., & Martínez-Carbonell, J. (2013). Injury incidence in judokas at the Spanish national university championship. *Archives of Budo*, 3. 211-218.
- Poulsen, M., & Johnson, D. (2011). Meniscal injuries in the young, athletically active patient. *The Physician and sportsmedicine*, 39(1). 123-130. DOI:10.3810/psm.2011.02.1870
- Terzidis, I., Christodoulou, A., Ploumis, A., Givissis, P., Natsis, K., & Koimtzis, M. (2006). Meniscal tear characteristics in young athletes with a stable knee: Arthroscopic evaluation. *The American Journal of Sports Medicine*, 34(7). 1170-1175. <https://doi.org/10.1177/0363546506287939>
- Wang, M., Yuan, Z., Ma, N., et al. (2017). Advances and prospects in stem cells for cartilage regeneration. *Stem Cells International*, 2017. 4130607. DOI:10.1155/2017/4130607
- Yeh, P., Starkey, C., Lombardo, S., Vitti, G., & Kharazzi, D. (2012). Epidemiology of isolated meniscal injury and its effect on performance in athletes from the National Basketball Association. *The American Journal of Sports Medicine*, 40(3). 589-594. <https://doi.org/10.1177/0363546511428601>
- Zedde, P., Mela, F., Del Prete, F., Masia, F., & Manunta, A. (2014). Meniscal injuries in basketball players. *Joints*, 2(4). 192-196.