Journal of Siberian Federal University. Humanities & Social Sciences 9 (2014 7) 1555-1566
~ ~ ~

УДК 930.26

Decapitations in Late Bronze Age and Iron Age sites from Sevan region (Armenia)

Anahit Yu. Khudaverdyan*
Institute of Archaeology and Ethnography
National Academy of Science
15 Charents Str., Yerevan, 0025, Republic of Armenia

Received 02.06.2014, received in revised form 21.07.2014, accepted 15.08.2014

The fact that rituals involving the sacrifice of people were present within the cultures of Late Iron Age Armenia has long been known. The purpose of this paper is to dig further towards the socio-cultural reasons behind such rituals, and to examine the evidence for how these rituals might have played out within the context of the cultures at the time. In order to establish the nature decapitation and function of this ritual as it pertained to the Late Bronze Age and Iron Age cultures of Armenia, a number of avenues will be explored. Studies of human skeletal materials from the Noraduz and Karmir, often excavated decades ago, may therefore reveal similar types of evidence. It is suggested that such studies will contribute significantly to our understanding of Late Bronze Age and Iron Age Armenia burial practices, and our ability to reconstruct social organization.
Detailed analysis of received traumas allowed reconstructing the circumstances of the females death. The heads were decapitated by sharp cutting weapon. Reconstruction of the death circumstances and archaeological context of the find suggest a ritual nature of the action. Within the culture of the time appeasing the gods was most likely the main stated reason for conducting such sacrifices. A sacrifices may also have been performed for the sake of something far less specific, for instance simply thanking the gods so as to be on relatively good terms with them.
Analyzed in this paper is the presence of cut marks, and tumpline deformation and cradle deformation on the decapitated skulls.

Keywords: Armenia, Late Bronze Age, Iron Age, decapitation, cut marks, tumpline and cradle deformations.

Introduction

Cutmarks on human bones have been associated with a variety of practices. Examples include decapitation, dismemberment, ritual sacrifices, violent death and secondary burial (Bush, Stirland 1991, p. 207; Larsson 1984, p. 34; 1990, p. 287; McKinley 1993, p. 43; Molleson 1981, p. 25).Various explanations for the physical act of decapitation in different groups from distinct periods have been put forward (Bridges et al. 2000, p. 47; Milner et al. 1991, p. 596; Smith 2003, p. 308; 2008, p. 592). Various researchers have outlined and refined these parameters which include: trophy-taking activities including decapitation, scalping, and removal of limbs or other body parts taken away by the attacker(s). In their study, Boylston et al. (2000, p. 248) discuss extensively the circumstances under which

* Corresponding author E-mail address: akhudaverdyan@mail.ru

decapitation may have occurred: " (1) as a form of corporal punishment in which an individual is executed by severing the head from the body through the use of an edged weapon; (2) as a consequence of armed confrontation in which the neck becomes a target in order to disable or kill a foe; (3) as a trophy of armed confrontation; (4) as a form of relic collection or veneration; (5) as a result of bloodletting in which the head is removed in order to collect the body's blood supply; (6) as a result of a mismanaged hanging; (7) as a result of a figurative association between the head and a quality or qualities considered to be associated with it". Damage to the upper cervical vertebrae (and also C7 or T1 in some instances), mastoid processes, occipital regions, the posterior parts of mandibles and first ribs have been considered as good markers (Anderson 2001, p. 402; Ardagna et al. 2005, p. 74; Aufderheide, Rodríguez-Martín 1998; Buckberry, Hadley 2007, p. 311;). Beheading-related traumas were also observed on the odontoid peg (McKinley 1993, p. 43) and transverse processes of vertebrae when anaxe rather than a sword has been used (Waldron 1996, p. 115). Even if no evidence has been left on the bones, some aspects of the burial context can be indicative of decapitation such as the absence of a head (although bones can eventually be destroyed or lost through post-depositional processes such as intrusive burials, animal activities, and environmental conditions) (Okumura, Eggers 2008, p. 18), the presence of a head without other postcranial elements (Nagaoka, Abe 2007, p. 166) or the placement of a head in a non-anatomical position (Boylston et al. 2000, p. 250). For many cultures, the most important trophy is the head, and its collection can be associated with war, religion, social prestige or cannibalism. The oldest known references to this practice of collecting skulls is found in the Bible. The custom of head taking was a widespread method among many cultures because the head of a vanquished foe represented the most unequivocal symbol of an enemy's defeat (Keeley 1996, p. 54). The deposition of human skulls has been interpreted as evidence for a headhunting cult, perhaps relating to enemy dead, whose deposition could provide symbolic protection (Wilson 1981, p. 163; Khudaverdyan et al. 2013, p. 76-83). The human skulls were believed to have also magical and curing effects (*Schmandt-Besserat* 2002, p. 115). The skull of a deceased person was believed to provide a way to communicate with the spirit of the dead and was used in divination (Ibid., p. 115). The skull also secured the use of the power to succeeding generations, perhaps this it placated the spirit, perhaps controlled it (Kenyon 1957, p. 45). Okumura, Siew (2013, p. 691) examine a collection of human skulls from Borneo. The textual evidence strongly argues that these skulls were meant as a form of dominance over other groups, and given the archaeological evidence for cutmarks and trauma, they are able to support the text and conclude that these were headhunting trophies and not a form of ancestor veneration.

Skull removal, or at least separate burial of crania, is known in the Iberomaurusian (Arambourg 1934, p. 21; Hachi 1996, p. 65) and has also been found for Late Natufian and PPNA sites in the south-central Levant (Kuijt 1996, p. 327). For the Levant, the skulls appear to have been removed after defleshing, since there were no cutmarks associated with the missing skulls. In Early: Late Natufian burials at various sites, the area of the head of the deceased was marked with rock cairns or individual stones (Byrd, Monahan 1995, p. 264), possibly to facilitate retrieval of the skulls later (Kuijt 1996, p. 333). There are societies, the ancient Greeks for example, who held the concept of voluntary self destruction as an integral part of the sacrificial ritual (Bremmer 2007, p. 5). This idea may have had some place within all instances of human sacrifice, as it dates back to the time of prehistoric hunters who would

view the slaying of their game as a voluntary act of self sacrifice on the part of the animal. Funerary rights were not solely reserved for the free or the in nocent, they may also have been performed for condemned criminals. Ancient Armenian groups believed in a pantheon of gods, many of whom possessed counterparts in the mythologies of other Indo-European groups, which would have been the objects of worship and the acceptors of the human sacrifices being performed. In the case of the ritual sacrifices that took place in Armenia during the Iron Ages it has been generally assumed that appeasing the gods was the main purpose of such bloody rituals (Khudaverdyan et al. 2013, pp. 76-83).

Two females from a Armenia burials show evidence of decapitation. The purpose of the study the reasons for decapitation are discussed. In the past two decades, studies of cutmarks on bones (human) have added important new insights into certain behavioural aspects of prehistoric peoples. We believe that the cutmarks found on the human skulls from 2 sites provide unique new evidence on burial customs. In this paper we present the results of the study of the cutmarks and, using the various lines of evidence, we provide an interpretive framework for the findings and briefly discuss the implications for reconstruction social organization.

Materials and methods

The present paper discusses human remains from 2 archaeological sites in Armenia. The sites is situated on a large expanse on the banks of the Sevan Lake (Fig. 1). In total the samples used for the present study consisted of 41 skulls (Table 1). Skeletons from Noraduz and Karmir are a part of collection gathered by Anna Palikyan. The absence of a published report on these materials at A.K. Palikyan. Unfortunately, in all cases only the skulls were preserved. The archaeological context, such as location of the site, and time period of the burial were recorded. The dating of sites rests on ceramic typology.

The material excavated of the Late Bronze Age and Iron Age (11–6 c. BCE) sheds light on various aspects of ancient life in this region, testifying convincingly that a complex culture existed all over the Sevan area. Of the materials discovered in these tombs there are a large number of rich ornamented ritual vessels, beads of stone and of precious metals, and other items. The Later Bronze Age and Iron Age saw the first widespread use of wheeled transport, for both agricultural and high-status/military purposes. There will also have been a need to move herds between grazing grounds.

Sex determination was carried out using cranial morphological markers (glabella, mastoid process, supra-orbital ridge, nuchal crest, parietal eminence, orbit, palate, occipital condyle, external occipital protuberance, styloid process, fronto-nasal junction, mandible, mental protuberance, and teeth) (Alekseev, Dedec 1964, pp. 29-34; Buikstra, Ubelaker 1994, pp. 16, 24–32). For subadults, dental development and eruption were used (Buikstra, Ubelaker 1994, p. 16; Moorrees et al. 1963a, pp. 205-213; 1963b, pp. 1490-1502; Ubelaker 1989, pp. 60-95). The skeletons were analysed macroscopically for evidence of decapitation. The metric traits considered to be of primary interest in population studies are summarised in J.E. Buikstra, D.H. Ubelaker (1994, pp. 85–94). Where preservation and completeness permit, a maximum of 37 measurements are taken from the adult skull (Alekseev, Dedec 1964, p. 49-75). Non-metric traits were recorded as recommended by A.A. Movsesyan et al. (1975, pp. 128-149).

Discussion

The first skull (Noraduz, burial 21) belong to an female of approximately 40 to 45 years of age at death. Postcranial skeleton has not been

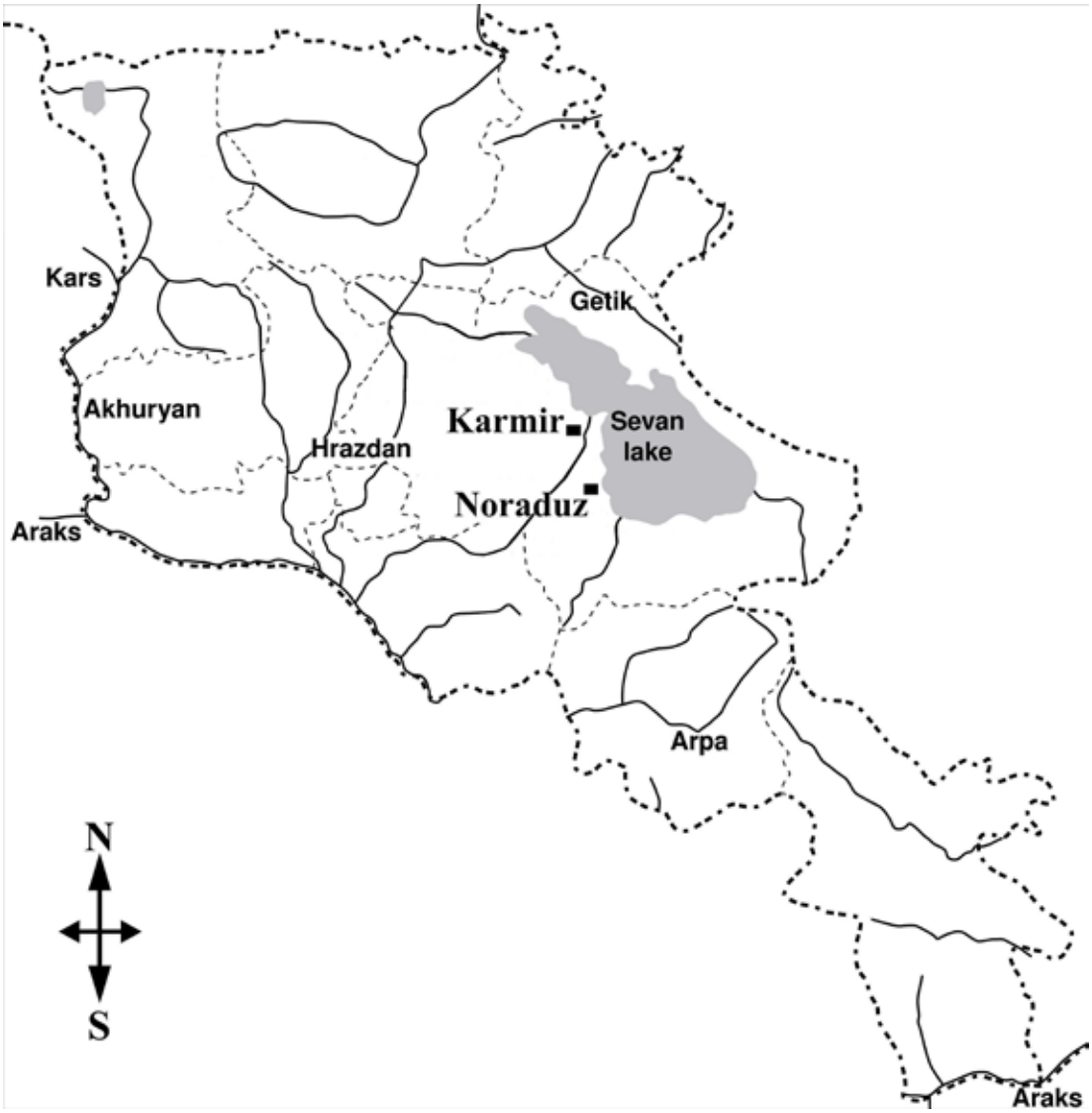

Fig. 1. Map of Armenia showing the location of the sites discussed in the paper

Table 1. Number of individuals from Armenian sites studied in this paper

Site	Sex	Age categories							
Chronology		0-10	11-19	20-29	30-39	40-49	50-59	60+	Total
Noraduz	male		1	2	3	4	3	4	17
Middle/Late Transitional	female		2	2	1		2	1	8
11th –6 th c. BCE	undet.	8	1		1				10
Karmir	male			2	1				3
Middle/Late Transitional 11th–8th c. BCE	female					1	1	1	3
Total		8	4	6	6	5	6	6	41

found. The following measurements (mm) were recorded from the skull: cranial length, 179; cranial breadth 136, minimal frontal breadth, 100,5; greatest frontal breadth, 124; occipital breadth, 118. The following traits were present: sutura frontalis, foramina supraorbitalia, os wormii suturae squamosum, os wormii suturae sagittalis and os wormii suturae lambdoidea.

On the skull has with post-coronal depression (Fig. 2), type tumpline deformation mentioned in T. Molleson (2007, pp. 11-12) which was positioned on both parietals and slightly posterior to the coronal suture. Whereas, the parietal pressure may result from activities, such as carrying loads with a band across the parietal bones (Fig. 3) and the load being behind the body, but this is only likely if the activity was started in early childhood years. A simple inspection skull from Noraduz indicates that there is no grooving (depression or concavity) on the temporal region of a caused by diagonal bandaging, and also any other kinds of grooving completely absent. Length of horizontal grooving 86,5mm, width 25 mm.

Cranial modification is observable in some societies which is neither intentional, when an infant was secured on a cradle board for a long time, whereby those portions of the head in direct contact with the board would be flattened (Daems, Croucher 2007, p. 7). As can be seen from the Fig. 4, there are modifications recognizable on the vault, a marked depression immediately above the lambda affecting mid-sagittal contour, resulting in an interparietal plane which covers nearly half of the sagittal suture.

At the skull pathological lesions were found. 1. Exostosis in the ear channel. The size of these exostoses may vary from small corrugations to large prominences almost filling the meatus. Exostosis formations in the ear canal are regarded as a marker of negative influence of cold water from diving (Kennedy 1986, p. 406; Manzi et al. 1991, p. 256). Exposure to wind and cold water causes the bone surrounding the ear canal to thicken and constrict the ear canal, sometimes to the point of complete blockage (known as “occlusion”). Other hypothesized causes of auditory exostoses include chronic infection or inflammation, genetics, and mastication stress (Aufderheide, Rodríguez-Martín 1998, pp. 254-255).

Cribra orbitalia (2) fixed on the both orbits: indicator of iron deficiency anemia. Iron



Fig. 2. Tumpline deformation (Noraduz, burial 21)

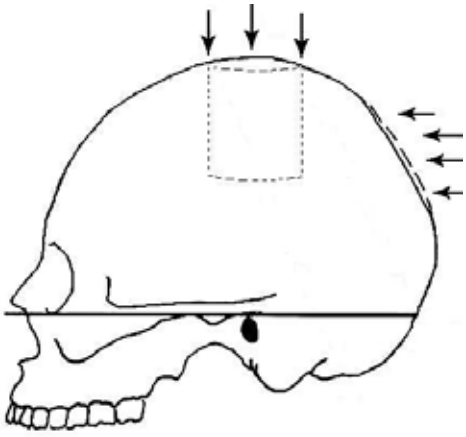

Fig. 3. Morphological changes of crania under the deformation processes

is essential for many body functions, such as oxygen transport to the body's tissues. When iron is deficient, whether as a result of nutritional deprivation, low body weight, chronic diarrhea, parasite infection, or other factors, the body attempts to compensate by increasing production of red blood cells (Walker 1986, p. 348). In infancy and childhood, iron-deficiency anemia is associated with impaired growth and delays in behavioral and cognitive development (Lozoff et al. 1996, p. 387; Walter et al. 1989, p. 11; Ryan 1997, p. 46). In adulthood, the condition is associated with limited work capacity and physical activity (Scrimshaw 1991, p. 48).

In 2014, we have documented the existence of the cutmarks (3) during a detailed examination of the skulls, while undertaking preliminary cataloguing and measurement. Evidence of decapitation clearly observed: damage to the mastoidal (Fig. 5). This is the only cutmark that could conceivably have been causally related to death. Mechanical breaks of a bone are received at the moment of death of the individual. Such kind of injuries have only one definition (beheading at the person who is in vertical situation) (Manchester 1983, p. 63).



Fig. 4. Cradle deformation (Noraduz, burial 21)

Fig. 5. Decapitation (Noraduz, burial 21)

The second skull (Karmir, burial 3) belong to an young female of approximately 20 to 25 years of age at death. The following measurements (mm) and observations were collected from the skull: cranial length, 184; cranial breadth, 139; minimum frontal breadth, 92,5; greatest frontal breadth, 116; occipital breadth, 114. The following traits were present: Os Incae, os wormii suturae lambdoidea, foramina spinosum.

In female combine two types (and tumpline, and cradle) deformation (Fig. 6), exostosis in the ear channel and cribra orbitale are observed.

An interesting feature in the case being analyzed in this paper is the presence of cut marks (Fig. 7) on the decapitation skull. In all cases marks showed edges that could be consistent with the intentional use of cutting instruments. The term "symbolic trephination" was proposed by Bartucs, who described them as "nonpenetrating damage", affecting the upper compact layer (substantia compacta) (cited by Mednikova 2004, p. 119). Symbolic trephinations could possibly simulate actual penetration into the cavity of the skull. This type of intervention did not necessarily involve a risk to life, as did a penetrating craniotomy. The symbolism could result from the localization of damage as, in the most of cases, the location was linked to cranial sutures or important anatomical points of the skull, which are interpreted as having had a sacral meaning. The object of the latter is unknown, ritual-medical reasons are as possible as religious

causes or higher social status. That presented cut marks distributed across both parietal bones (Fig. 8) which could be related to said process. These rituals consecrated social integration, the act of becoming a person, once the spiritual energy had been fixed inside in the individuals body.

In the basis of a skull of the individual mechanical break of left occipital condyle and damage of the left mastoidal were noted (Fig. 8). Mechanical breaks of a bone are received at the moment of death of the individual. We noted, such kind of injuries have only one definition (beheading at the person who is in vertical situation) (Manchester 1983, p. 63). At the left from the outer side and specific destructions of left occipital condyle say a linear break of an mastoidal that the blow was struck behind, obviously, by the right-handed person. The man had suffered an injury to the head from a sharp object, presented also the destructions and crevasses. Holding by hair the victim, the head of the individual cut a sword.

The skull from Karmir had not only been decapitation prior to death but also had blow to the head. This example provides a good case for the assertion that not only were individuals such as this being ritually murdered but also that violence and perhaps played a very important role in such sacrifices. This indicates that symbolism

Fig. 6. Combine two types (and tumpline, and cradle) deformations (Karmir, burial 3)

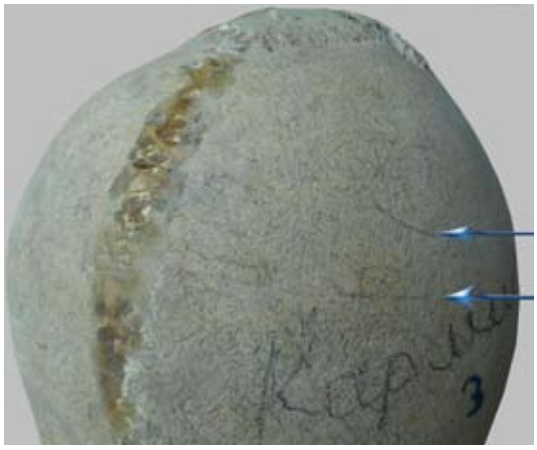

Fig. 7. Cut marks (Karmir, burial 3)

Fig. 8. Decapitation (Karmir, burial 3)

and perhaps the whole spectacle of the execution was essential to the ritual. Many human remains in Bronze Age and Iron Age from Armenia carry marks of wounds and violent deaths (Khudaverdyan 2014, pp. 32–50).

Conclusion

A ritual is a coordinated act which an individual or group carries out in order to fulfill a particular social function, usually meant to bring solidarity or enforce social roles within the community, always characterized by having demonstrative, exaggerative, and repetitive qualities (Hughes 1991, pp. 1-2). In order for the gods to be of any help, they must first have been reimbursed for the violent energies being expended. For Bronze Age and Iron Age from Armenia, there are not any ethnohistoric documents that can be used as a source of information. The important information provided by the osteological data concerns the process of decapitation. Is no other published osteological research on decapitation heads from Armenia in Late Bronze Age and Iron Age. If the decapitation in Armenia sites had a more ritualized form, perhaps associated to fertility rites. The traumatic injuries on the crania suggest that the excision points are very close to mastoid processes, indicating beheaded individuals were probably motionless, having been severely injured, under which circumstances, them managed to precisely cut off the exact bodyparts that they wanted (Okumura, Siew 2008, p. 18).

For a community to feel the need to make such a highly valued offering to the gods the ritual must have been of critical importance. Such an enormous gift must have necessitated an equally enormous reciprocal blessing from the gods or even a miracle of sorts. It is quite possible that in such cases the community may have been in great peril or under the misery of epidemic disease, so as to necessitate such an enormous sacrifice. In Armenia in Bronze Age and Iron Age, practiced human sacrifice rituals, apparently preferred young and middle adult females as their victims. It is generally assumed that women in pre-state societies were engaged in domestic production while men practiced animal husbandry, ploughed, hunted, fought and processed metals. We can accept with some confidence that there a women primarily engaged in activities such as food processing, agricultural work, pottery making and child-rearing. Positive correlations exist between the females and the agricultural works for that region. Cranial modification is observable in some societies which is neither intentional, the parietal pressure may result from activities, such as carrying loads with a band across the parietal bones and the load being behind the body. Socio-economic status of the victim also played an important role in determining the value of the sacrifice. The higher the status that a person had the greater the sacrifice would be. In Armenia, to choose a characteristic example, the would-be leader achieves and maintains his ambi- tions by demonstrating his abilities as a warrior, ceremonial leader, food producer, etc. Slaves and prisoners may have been sacrificed more readily, and certainly more frequently, than a well established individual but in no way were people of the upper class off limits from being made sacrifice to the gods. However, whether the people of this time were conscious of it or not, the sacrifices had other uses and motives.

Although this study is the first to report cutmarks on Late Bronze and Iron Age human skulls from the Sevan Lake, there is evidence for decapitation and dismemberment at other sites. For example, Shirakavan and Lori Berd groups (Late Iron Age) yielded many isolated fragments of crania, mandibles, teeth, and postcranial remains, and A. Yu. Khudaverdyan et al. (2013, pp. 78-83) concluded that the position of the bones and fragments indicated

decapitation and dismemberment prior to burial. It was concluded that the finds represents of a decapitated individual. This suggests to us that more human remains from this area, often excavated decades ago, may show similar types of evidence.

References

1. Alekseev V. P., Dedec G. F. *Kraniometria (metodika antropologicheskikh issledovanii)* [Craniometry (methodology of anthropological research)]. Moscow: Nauka, 1964. 128 p.

2. Anderson, T. (2001). Two decapitations from Roman Towcester. *Int J Osteoarchaeol, 11*, 400-405.

3. Arambourg, C. (1934). Géologie, paléontologie, archéologie. *Les Grottes Paléolithiques des Beni Segoual* (*Algérie*), Arambourg, C., Boule, M., Vallois, H. & Verneau, R. (eds.). Paris, Archives de l'Institut de Paléontologie Humaine, Mém. 13, pp. 1–35.

4. Ardagna, Y., Richier, A., Vernet, G. & Dutour, O. (2005) A case ofbeheading dating from the Celtic Period (La Tène B.Sarliève-Grande Halle, France). *Int J Osteoarchaeol, 15*, 73-76.

5. Aufderheide, A. C., Rodriguez-Martin, C. (1998). *The Cambridge Encydopedia of Human Paleopathology.* Cambridge University Press, Cambridge. 496 p.

6. Bremmer, J. N. (2007). The Strange World of Human Sacrifice (Proceedings of a conference held in winter 2004 at the Rijksuniversiteit Groningen). Peeters-Bondgenotenlaan 153-B-3000 Leuven, Dudley, MA, Peeters. 268 p.

7. Bridges, P. S., Jacobi, K. P., Powell, M. L. (2000). Warfare-related trauma in the late prehistory of Alabama. *Bioarchaeological Studies of Life in the Age of Agriculture: A View From the Southeast,* Lambert P. M. (ed.).University of Alabama Press, Tuscaloosa, pp. 35–62.

8. Boylston, A., Knüsel, C. J., Roberts, C. A. & Dawson, M. (2000) Investigation of a Romano-British Rural Ritual in Bedford, England. *Journal of Archaeological Science,* 27, 241-254.

9. Byrd, B. F., Monahan, C. M. (1995). Death, mortuary ritual, and Natufian social structure. *Journal of Anthropological Archaeology*, 14, 251–287.

10. Buckberry, J. L., Hadley, D. M. (2007). An Anglo-SaxonExecution Cemetery at Walkington Wold, Yorkshire. *Oxford Journal of Archaeology,* 26, 309–329.

11. Buikstra, J. E., Ubelaker, D. H. (1994). Standards of data collection from human skeletal remains. Arkansas Archaeological Survey Research Series 44. Fayetteville. 218 p.

12. Bush, H., Stirland, A. (1991). Romano-British decapitation burials: a comparison of osteological evidence and burial ritual from two cemeteries. *Anthropologie*, XXIX, 205–210.

13. Daems, A., Croucher, K. (2007). Artificial cranial modification in Prehistoric Iran: evidence from crania and figurines. *Iranica Antiqua,* XLII, 1-21.

14. Hachi, S. (1996). L'Ibéromaurusian, découverte des fouilles d'Afalou (Bédjaîa, Algérie). *L'Anthropologie*, 100, 55–76.

15. Keeley, L. (1996). War Before Civilization: The Myth of the Peaceful Savage. Oxford, Oxford University Press. 272 p.

16. Kennedy, G. E. (1986). The Relationship Between Auditory Exostoses and Cold Water A Latitudinal Analysis. *Am J Phys Anthropol*, 71, 401-415.

17. Kenyon, K. (1957). Digging Up Jericho: The Results of the Jericho Excavations, 1952-1956. London, Earnest Benn Associates. 282 p.

18. Khudaverdyan A. Yu., Devejyan S. G. & Eganyan L. G. Sposoby obrashcheniia s telami umershikh v paiytnikakh Shirakavan i Lori Berd (Armeniia) [Process for handling of dead bodies in the monuments Shirakavan and Lori Berd (Armenia): according to paleoanthropology]. *Bulletin of archeology, anthropology and ethnography*, 2013, No 4 (23), 72-85.

19. Khudaverdyan, A. (2014). Trauma in human remains from Bronze Age and Iron Age archaeological sites in Armenia. *Bioarchaeology of the Near East*, *8*, 29–52.

20. Kuijt, I. (1996). Negotiating equality through ritual: A consideration of Late Natufian and Prepottery Neolithic A period mortuary practices. *Journal of Anthropological Archaeology*, *15*, 313–336.

21. Larsson, L. (1984). The Skateholm Project. A Late Mesolithic settlement and cemetery complex at a southern Swedish bay. *Papers of the Archaeological Institute*, *University of Lund* 1983–1984 (new series), *5*, 5–38.

22. Larsson, L. (1990). The Mesolithic of Southern Scandinavia. *Journal of World Prehistory*, 4, 257–309.

23. Lozoff, B., Wolf A.W. & Jimenez E. (1996). Iron-deficiency anemia and infant development: effects of extended oral iron therapy. *Journal of Pediatrics 129*, 382-389.

24. Manchester K. (1983). The archaeology of discase. Bradford. 100p.

25. Manzi, G., Sperduti, A., Passarello, P. (1991). Behavior-Induced Auditory Exostoses in Imperial Roman Sodety: Evidence from Coeval Urban and Rural Communities Near Rome. *Am J Phys Anthropol*, *85*, 253-260.

26. McKinley, J. I. (1993). A decapitation from the Romano-British cemetery at Baldock, Hertfordshire. *Int J Osteoarchaeol*, *3*, 41–44.

27. Mednikova M. B. Trepanatsii v drevnem mire i kul‘t golovy [Trepanation in the ancient world and the cult of the head]. Moscow: Aleteia, 2004. 208 p.

28. Milner, G. R., Anderson, E. & Smith, V. G. (1991). Warfare in late prehistoric west-central Illinois. *American Antiquity, 56*, 581–603.

29. Molleson, T. (1981). The archaeology and anthropology of death: what the bones tell us. *Mortality and Immortality - The Anthropology and Archaeology of Death,* Humphreys, S. C., King, H. (eds.). London, Academic Press Inc., pp. 15–32.

30. Molleson, T. (2007). A method for the study of activity related skeletal morphologies. *Bioarchaeology of the Near East*, *1*, 5–33.

31. Moorrees, C. F., Fanning, E. A. & Hunt, E. E. (1963a). Formation and resorption of three deciduous teeth in children. *Am J Phys Anthropol, 21*, 205-213.

32. Moorrees, C. F., Fanning, E. A. & Hunt, E. E. (1963b). Age variation of formation stages for ten permanent teeth. *JDR*, *42*(6):1490-1502.

33. Movsesyan, A. A, Mamonova, N. N. & Richkov, Y. G. Programma i metodika issledovaniia anomalii cherepa [The program and method of research of anomalies of a skull] *Anthropology questions*, 1975, Vol. 51, 127-150.

34. Nagaoka, T., Abe, M. (2007). Human skeletal remains from the Osaka castle site in Japan: metrics and weapon injuries. *Anthropological Science,* 115, 163–168.

35. Okumura, M. M. M., Eggers, S. (2008). Natural and cultural formation processes on the archaeological record: acase study regarding skeletal remains from a Brazilianshellmound. *Archeology Research Trends,* Suárez, A. R.,Vásquez, M. N (eds). Chapter 1. New York, Novascience, pp. 1-39.

36. Okumura, M., Siew, Y. Y. (2013). An Osteological Study of Trophy Heads: Unveiling the Headhunting Practice in Borneo. *Int J Osteoarchaeol, 23*, 685-697

37. Ryan, A. S. (1997). Iron-deficiency anemia in infant development: implications for growth, cognitive development, resistance to infection, and iron supplementation. *Yearbk Phys Anthropol*, *40*, 25-62.

38. *Schmandt-Besserat*, *D. (*2002). From *Behind the Mask*: *Plastered Skulls from Ain Ghazal*. *Origini*, *24*, *95-140*.

39. Scrimshaw, N. (1991). Iron deficiency. *Sci Am 265*(4) (October):46-52.

40. Smith, M. O. (2003). Beyond Palisades: The Nature and Frequency of Late Prehistoric Deliberate Violent Trauma in the Chickamauga Reservoir of East Tennessee. *Am J Phys Anthropol, 121*: 303-318.

41. Smith, M. O. (2008). Adding Insult to Injury: Opportunistic Treponemal Disease in a Scalping Survivor. *Int J Osteoarchaeol, 18*: 589-599.

42. Ubelaker D. *Human skeletal remains: Excavation, analysis, interpretation*. Washington: Taraxacum, 1989. 172 p

43. Waldron T. (1996). Legalized trauma. *Int J Osteoarchaeol, 6*: 114–118.

44. Wilson, C. E. (1981). Burials within settlements in Southern Britain during the pre-Roman Iron Age. *Bulletin of the Institute of Archaeology (University of London),* 18: 127-170.

45. Walker, P. L. (1986). Porotic Hyperostosis in a Marine-Dependent California Indian Population. *Am J Phys Anthropol*, *69*: 345-354.

46. Walter, T., Andraca I., Chadud P. & Perales C. G. (1989). Iron deficiency anemia: adverse effects on infant psychomotor development. *Pediatrics*, 84:7-17.

Am J Phys Anthropol	American Journal of Physical Anthropology
Int J Osteoarchaeol	International Journal of Osteoarchaeology
JDR	Journal of Dental Research
Yearbk Phys Anthropol	Yearbook of Physical Anthropology
Sci Am	Scientific American

Обезглавливания в эпоху поздней бронзы и в железном веке в группах из Севанской области (Армения)

А.Ю. Худавердян
Институт археологии и этнографии НАН
Республика Армения, 0025, Ереван, ул. Чаренца, 15

В статье выдвигаются реконструкции жизни и смерти двух индивидов из могильников эпох поздней бронзы и железного века с территории Севанского бассейна Армении. На черепах наблюдались нарушения целостности костей черепа, связанные с травматическими последствиями. Факты, связанные с жертвоприношениями, уже были известны по материалам позднего железного века. Целью данной работы является предоставление новых данных о практике обезглавливания (по материалам могильников Норадуз и Кармир), а также реконструкция возможных причин и мотивов, побуждающих людей к совершению подобных ритуалов. В культуре того времени умиротворение богов требовало выполнения ритуалов жертвоприношений. На поверхности теменных костей у индивида из Кармира обнаружены рубцы (символические трепанации). На черепах у отмеченных индивидов наблюдались локальные понижения поверхности теменных костей (tump-line) в области за брегмой. Их можно интерпретировать как следствие ношения достаточно широкой повязки, скрепленной ремнем, удерживающей груз на спине. Корзина с грузом приводит к поперечному понижению костей черепа. Данный тип непреднамеренной деформации можно назвать социально-бытовым. Другой деформированный участок – в затылочной области на теменных костях. Непреднамеренная затылочная деформация являет следствием длительного пребывания ребенка в твердой колыбели («бешик»), отчего образуется уплощение части темени.

Ключевые слова: Армения, поздняя бронза, железный век, обезглавливание, срезанные знаки, деформации – теменная и колыбельная.